

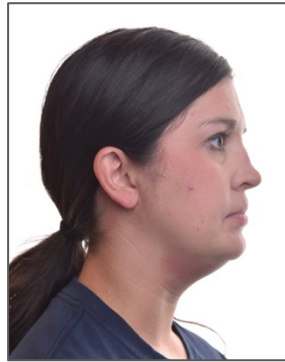
# Protocol for Therapeutic Photographs

*Therapeutic models require a set of standard photos (3 facial, 5 intraoral) taken within 4 weeks before or 2 weeks after the scan. The "full mouth" photo is strongly recommended. Required x-rays: a current panorex and a current or previously imported ceph.*




## Front

- Patient looking forward
- Head leveled
- Lips together & relaxed
- Capture collarbone, top of head
- Ears must be visible



## Profile

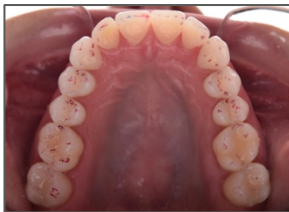- Hair behind ears
- Lips together & relaxed
- Patient looking forward
- Capture collarbone



## Smile

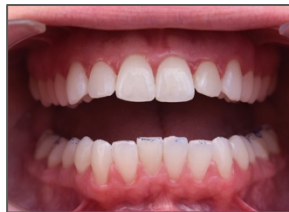- Patient looking forward
- Head leveled
- Patients' natural smile
- Capture collarbone, top of head
- Ears must be visible

*\*submit additional photo if 3-3 not in view\**



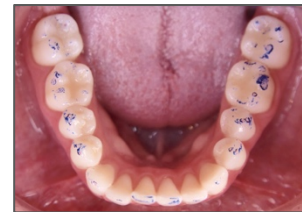
## Upper Occlusal

- Use articulating paper
- Take reflection of photo in mirror
- Rest mirror behind lower molars
- Capture all teeth including 2<sup>nd</sup> molars



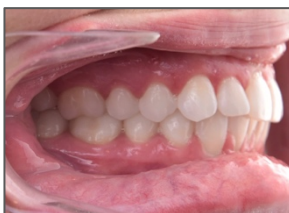## Full Mouth

- Slightly open to see incisal edges
- Capture from 7-7



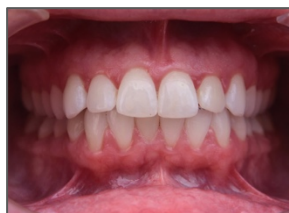## Lower Occlusal

- Use articulating paper
- Take reflection of photo in mirror
- Retract tongue with mirror
- Rest mirror behind upper molars
- Capture all teeth including 2<sup>nd</sup> molars



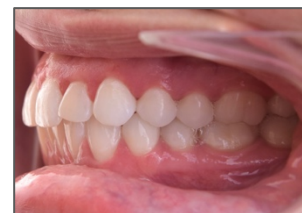## Right Buccal

- Capture class relation of bite
- Straight wire of cuspid, bicuspid & molars
- Capture 1<sup>st</sup> cusp tip of 2<sup>nd</sup> molar
- Use buccal mirrors if necessary



## Frontal

- Patients' true bite
- Parallel to occlusal plane & centered
- Capture 7-7



## Left Buccal

- Capture class relation of bite
- Straight wire of cuspid, bicuspid & molars
- Capture 1<sup>st</sup> cusp tip of 2<sup>nd</sup> molar
- Use buccal mirrors if necessary

SureSmile<sup>®</sup>  
Aligner